



PATIENT

Ripple Savic

PRESENTING CLINICAL SIGNS

History: Grade 3/6 heart murmur. Asymptomatic. Assess prior dental. Sedated with Gabapentin.

SPECIES

Feline

ECHOCARDIOGRAM FINDINGS

2D, m-mode, color flow and doppler imaging is available. The left ventricular wall is normal in dimension. There is a diffusely hyperechoic endocardium consistent with fibrosis. The papillary muscles are mildly remodeled and hyperechoic. The endocardium also appears remodeled. The left atrium is normal in size. The right atrium is normal in size. The right ventricle appears normal. The mitral valve is normal in structure and mobility. Blood flow through the LVOT is normal on Spectral; however, an intermittent obstruction suspected on color flow and 2D imaging. The RVOT velocity is mildly elevated with a dynamic appearance. No pleural or pericardial effusion seen. No obvious cardiac tumors.

BREED

DSH

SEX

Male Neutered

CARDIAC CHART

AGE

9 years

FELINE CARDIAC PARAMETERS	BODY WEIGHT (kg)	HR (BPM)	IVSd (cm) (Moise, Pipers)	LVIDd (cm) (Moise, Pipers)	LVWd (cm) (Moise, Pipers)	FS (%)	EF (%)
NORMAL PARAMETER	-----	150-240	0.35-0.55	<2 (mean 1.5)	3.5-0.55	35-67	80-100
PATIENT	5.3	60	0.48	1.55	0.48	60	91
FELINE CARDIAC PARAMETERS	LA/AO (Boon)	LA/AO HEART BASE (Swe) (Abbott)	LA 2D short axis Base view (cm) (Abbott)	LVOT VEL (m/s)	RVOT VEL (m/s)	E max (m/s)	
NORMAL	<1.5	<1.3	<1.2	<1.6	<1.3	<0.9	
PATIENT	1.4	1.3	1.2	1.6	2.0	NM	

WEIGHT

11.6lbs

INTERPRETED BY

Maggie Machen Lamy,
DVM DACVIM
(Cardiology)

**Note: All measurements based upon multi-modal images and methods. An average value is reported.*
Adapted from June Boon, Veterinary Echocardiography, 1998
Abbott J & MacLean H JVIM 2006;20: 111-119, Moise et al. Am J Vet Res 47:1476, 1986. Pipers et al. Am J Vet Res 40:882, 1979.

IMAGING PERFORMED BY

Crystal Hill, RVT

INTERPRETATION OF THE FINDINGS & FURTHER RECOMMENDATIONS

Overtly normal cardiac structure and function. The LV wall thickness is normal and there is no evidence of elevated left atrial pressure. There is mild remodeling and fibrosis of the left ventricular wall, which is likely a normal variant. Serial echocardiography will be necessary to determine progression. The murmur appears to be due to a dynamic RVOT and LVOT obstruction, which both appear benign in light of normal wall thickness. No additional issues are identified.

HOSPITAL NAME

Oxford County Vet
Clinic

REFERRING VET

Dr. Bowcott

Given these findings, no medications are indicated.

INVOICE

28349

No cardiac contraindication for general anesthesia. Mild IV fluid restriction is advised. Risk for complication with steroid use typically follows LA dilation, which in this case is low. That being said, any cat can experience unexpected signs of intolerance and monitoring of RR/RE is advised particularly in the initiation phase.

DATE

1/16/23

Recommend recheck echocardiogram in 1 year to screen for development of disease the



PATIENT

Ripple Savic

pre-existing murmur may mask.

SPECIES

Feline

BREED

DSH

SEX

Male Neutered

AGE

9 years

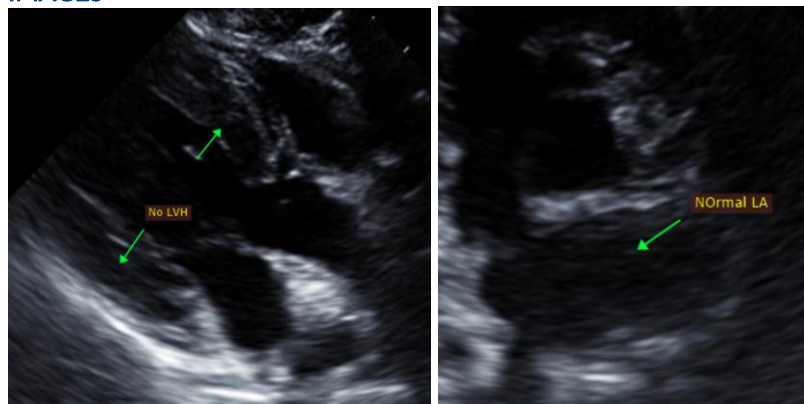
WEIGHT

11.6lbs

INTERPRETED BY

Maggie Machen Lamy,
DVM DACVIM
(Cardiology)

IMAGES



The information and recommendations provided are based on the images presented by the referring veterinarian. No evaluation can be communicated regarding pathology that was not visible in the image/video clips provided.

Thank you for this referral. This report was generated using transcription software, and minor dictation errors may be present. If the clinical or image interpretation does not parallel your findings or if I can be of any further assistance, please contact me.

Maggie Machen Lamy, DVM

Diplomate of the American College of Veterinary Internal Medicine (Cardiology)

info@sonopath.com

IMAGING PERFORMED BY

Crystal Hill, RVT

HOSPITAL NAME

Oxford County Vet
Clinic

REFERRING VET

Dr. Bowcott

INVOICE

28349

DATE

1/16/23